

Squamous Cell Carcinoma in the Shadow of the Mature Cystic Teratoma of the Ovary: A Case Report

Fatemeh Shafizadeh¹ , Sara Babazadeh^{2*} , Fatemeh Nasiri Amiri³ , Ahmadrza Shafizadeh⁴ 

1. Department of Obstetrics and Gynecology, School of Medicine, Babol University of Medical Sciences, Babol, Iran
2. Department of Pathology, School of Medicine, Babol University of Medical Sciences, Babol, Iran
3. Infertility and Reproductive Health Research Center, Health Research Institute, Babol University of Medical Sciences, Babol, Iran
4. Student Research Committee, School of Medicine, Babol University of Medical Sciences, Babol, Iran



Article Info

 [10.30699/jogcr.6.4.233](https://doi.org/10.30699/jogcr.6.4.233)

Received: 2020/02/17;

Accepted: 2021/05/29;

Published Online: 11 Aug 2021;

Use your device to scan and read the article online



Corresponding Information:

Sara Babazadeh,
Department of Pathology, School of
Medicine, Babol University of Medical
Sciences, Babol, Iran
Email: babazadehsara4@gmail.com

ABSTRACT

Mature cystic teratomas, also named dermoid cysts, are the most benign ovarian germ cell tumors and can occur in any age group. Transformation of the mature elements within the dermoid cyst to the malignancy termed mature cystic teratomas (MCTs) with malignant transformation occurs in only 1-2 % of cases. Of these, squamous cell carcinoma (SCC) with 80% prevalence is the most common type. A 54-year-old perimenopausal woman -gravida 5, para 4, live 4, and abortion 1- presented to Omid Clinic of Ayatollah Rouhani Hospital in Babol, Iran, with a complaint of abdominal pain for about five months. Transvaginal ultrasonography revealed a mass with a diameter of 125-millimeter in the left adnexa with a complex appearance containing fine-echo liquid, solid internal component, and thickened wall. Spiral CT scan of abdomen & pelvis showed 147×121-millimeter bilocular lesion consistent with an ovarian dermoid cyst. Left salpingo-oophorectomy was performed, and a frozen section was requested during the surgery, which showed a malignant epithelial tumor consistent with squamous cell carcinoma arising in teratoma. Total abdominal hysterectomy, bilateral salpingo-oophorectomy, pelvic lymphadenectomy, and partial omentectomy were done successfully. The patient was discharged from the hospital after two days without any complaints or adverse events. Regarding the rarity of MCT with malignant transformation, it is recommended to consider patient characteristics, preoperative imaging, laboratory evaluations, and the results of the frozen section during surgery since they can significantly change the treatment plan and the prognosis of the patient.

Keywords: Cystic, Dermoid Cyst, Mature cystic teratomas, Squamous cell carcinoma, Teratoma



Copyright © 2021. This is an original open-access article distributed under the terms of the Creative Commons Attribution-noncommercial 4.0 International License which permits copy and redistribution of the material just in noncommercial usages with proper citation.

Introduction

Mature cystic teratomas (MCTs) of the ovary, commonly named dermoid cysts, are the most benign ovarian germ cell tumors (GCTs), comprising up to 30% of all ovarian tumors (1). These are frequently unilateral, multicystic, and can occur in any age group (2). They could include an admixture of elements of three germ cell layers: ectoderm, mesoderm, and endoderm. Pathologically, teratomas are classified into three groups: mature (cystic/solid, benign), immature (malignant), and monodermal (3). Clinical presentation may vary from symptoms free to acute abdominal pain caused by adnexal torsion, rupture, or hemorrhage of the cysts (4). Malignant transformation develops in less than 2% of ovarian dermoid cysts (5). Squamous cell carcinoma (SCC) with 80% prevalence is the most common type (6). Herein, we report a 54-year-old peri-

menopausal woman who had referred with the complaint of chronic abdominal pain. During imaging evaluations, and abdominal mass was reported suggestive for MCT, and was histologically approved as SCC. The main purpose of this case report was to emphasize that although most of the adult mature teratoma are benign, there is a possibility of malignancy in any parts, so it's crucial to consider possibility of malignancy in such cases for choosing further appropriate treatment strategy. The specialist ought to be prepared to come across any threatening change.

Case Presentation

Patient Information

A 54-year-old woman -gravida 5, para 4, live 4 (all of them were normal vaginal delivery), and abortion 1 with dilation and curettage- presented to Omid Clinic of Ayatollah Rouhani Hospital in Babol, Iran, with a complaint of abdominal pain lasting for about five months. She also mentioned abdominal fullness sensation in the hypogastric area but didn't mention any other related symptoms. She was amenorrhea for nine months, a known case of thalassemia minor, and had a history of thyroid surgery due to hyperthyroidism.

Diagnostic Assessment

On the initial physical examination, there was no abnormality in the head, neck, and chest examination, but in the abdominal examination, there was a palpable

mobile mass with at least 14-centimeter (cm) diameter in the left lower hypogastric area with mild tenderness. Fundal height was not measurable. Also, cervical motion tenderness was negative. At first, transvaginal ultrasonography was requested, which revealed a mass with a diameter of 125-millimeter (mm) in the left adnexa with a complex appearance containing fine-echo liquid, solid internal component, and thickened wall. The ovaries were not visible, but the uterus volume (52×27× 40 mm), myometrium echogenicity, and endometrial thickness (1.2 mm) were normal, and no free-fluid in the pelvic cavity was reported. Due to the suspicion of the ovarian mass, laboratory tests including complete blood count, serum β-HCG, TSH, free T4, LDH, Alpha-Fetoprotein (AFP), carcinoembryonic antigen (CEA), CA-125, and Human epididymis protein 4 (HE4) were requested, results of which are expressed in [Table 1](#).

Table 1. Initial laboratory evaluations

Test	Result	Unit	Normal range
TSH	4.7	MIU/L	0.3-6
CEA	3.1	ng/mL	Less than 4
BHCG	2	Miu/mL	Negative <15
Free T4	6.4	pmol/L	12-22
CA 125	33	U/mL	0-35
HE4	88	Pmol/L	<140
AFP	2.2	IU/mL	Less than 5
LDH	393	U/L	207-414
Roma Index	28.9	%	

By considering laboratory results and ultrasonographic findings, laparotomy was scheduled for the patient, but because of some family conflicts, the surgery was postponed. After two months, the patient returned complaining of aggravation of pain. Still, no other symptoms, so spiral CT scan of abdomen & pelvis with intravenous contrast was requested, which showed a 147×121 mm bilocular lesion containing fat and fat fluid level and small intralesional tooth shape calcification in the left adnexa consistent with an ovarian dermoid cyst. Also, moderate left pleural effusion was noted. Based on the above finding, the patient was a candidate for left oophorectomy.

Therapeutic Interventions

During laparotomy, an irregular-shaped mass with an intact capsule containing multiple cysts and adipose tissue with approximate dimensions of 15×13×10.5 cm removed entirely ([Figure 1](#)), left salpingo-oophorectomy performed, and the specimen was sent for frozen sections and intraoperative pathological consultation. On gross examination, an unopened solid cystic creamy-yellowish mass measuring 15×13×10.5 cm, containing hair shafts, sebum, teeth, and turbid mucoid

yellowish fluid is seen ([Figure 2](#)). The maximum wall thickness of the cyst measured 2 cm. Frozen sections showed malignant epithelial tumors consistent with squamous cell carcinoma arising in teratoma. Then, total abdominal hysterectomy, bilateral salpingo-oophorectomy, pelvic lymphadenectomy, and partial omentectomy were done successfully, and the patient was transferred to the recovery room in stable general condition. According to permanent sections of mass, a final diagnosis of moderately differentiated squamous cell carcinoma arising in mature cystic teratoma was made (ICD-O: C56.9) ([Figure 3](#)). Since no lymph node is identified in the histological examination, tumor pathologic staging was determined at least stage IA (pT1a Nx Mx). Complementary Immunohistochemical Staining for P63 was also performed and showed strongly diffuse positive results in tumoral cells ([Figure 4](#)).

Follow-up and Outcomes

After two days of hospitalization, the patient was discharged from the hospital in good general condition without any complaints or adverse events. The patient was referred to a radio-oncologist to continue the treatment process and receive chemotherapy regimen.

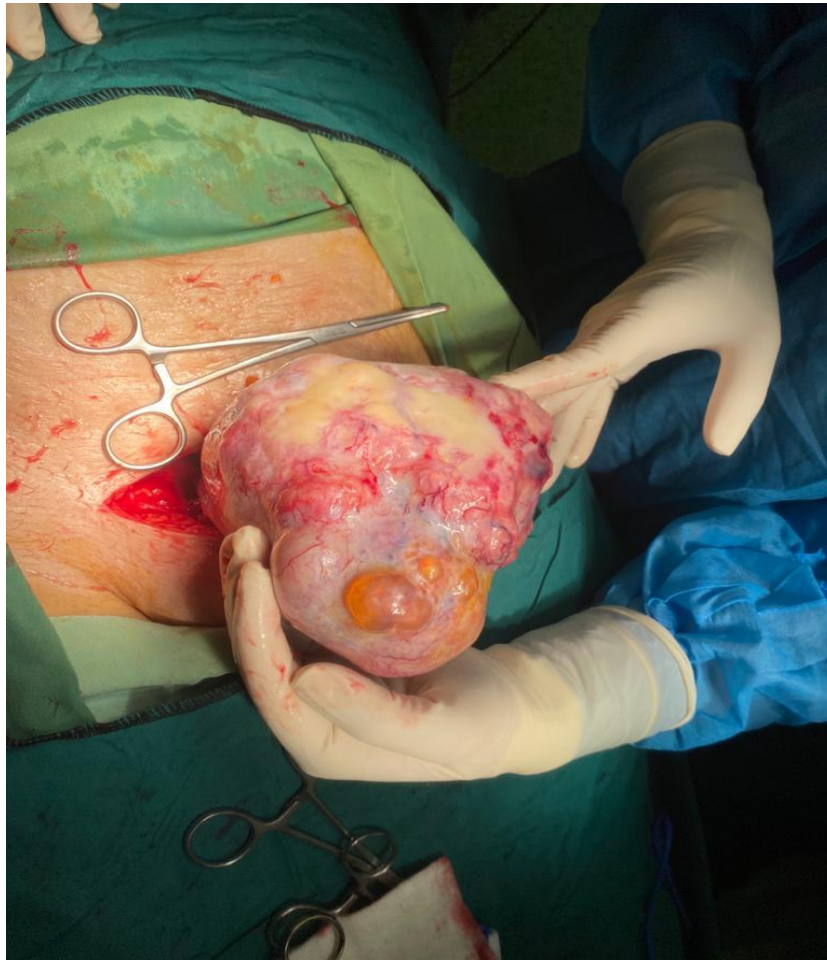

Figure 1. Irregular-shaped mass containing multiple cysts and adipose tissue

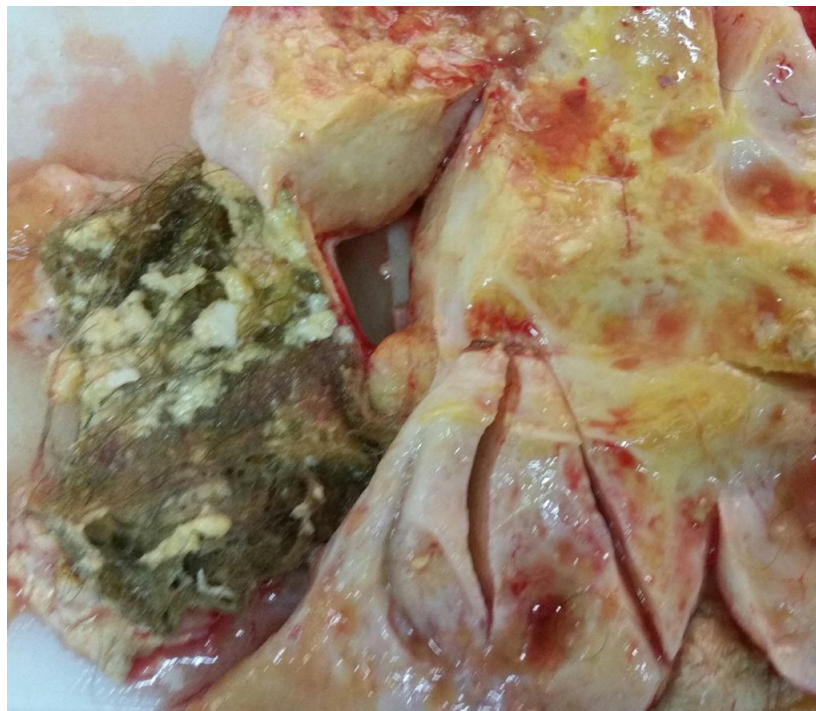

Figure 2. Admixture of sebum, hair within cavity of ovarian mass

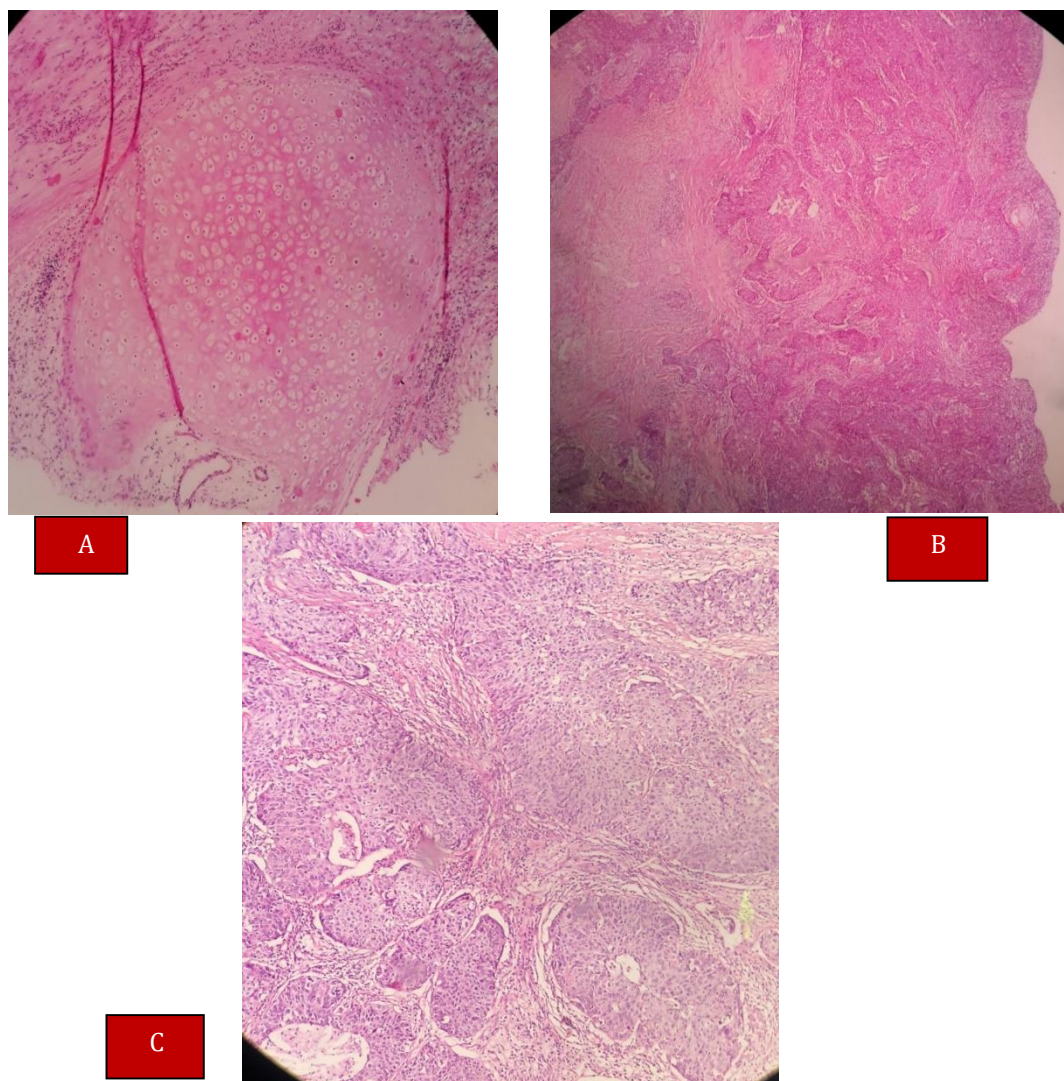


Figure 3. A) Microphotograph of ovarian mass: mature cartilaginous tissue that is a component of teratoma, B) Microphotograph of ovarian mass: Squamous cell carcinoma arising in MCT (Hematoxylin and Eosin stain $\times 100$), C) Microphotograph of ovarian mass; Sheets of malignant squamous cells in MCT (Hematoxylin and Eosin stain $\times 400$)

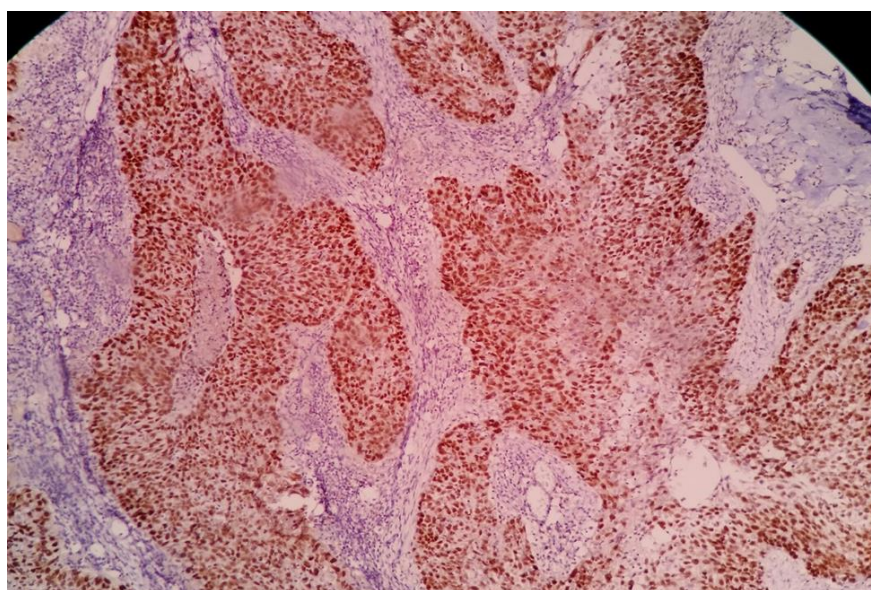


Figure 4. Immunohistochemical Staining for p63 showing strongly diffuse nuclear positivity in tumoral cells.

Discussion

The mean age of patients with the transformation of the ovarian dermoid cysts, with higher frequency among postmenopausal patients, is around 50 years old, in both SCC and non-SCC tumors (7). In this case, the result was similar to the findings in the literature. While the mature teratomas with 10-20% prevalence are the most common type of GCTs (8), 0.17-2 % of them may undergo malignant transformation, of which 80% are SCC(9). Despite the non-specific clinical manifestation, chronic abdominal pain and palpable mass with the prevalence of 47.3% and 26 %, respectively are more common based on the recent systematic review (10). As in our patient, stage 1 accounted for half of all SCC arising from MCT and also had a significantly better prognosis than other stages (10). Also, the Patient's age and menopausal status, preoperative imaging, and laboratory evaluations, despite their non-specificity, may have an association with treatment strategy and prognosis in these patients (11). For example, a tumor size ≥ 10 cm may be indicative of malignant transformation. As far as we know, if MCTs are discovered during the postmenopausal period, the likelihood of malignant transformation is very strong. Also, it seems there is an association between the presence of the high-risk human papillomavirus (HPV) infection and induction of the malignant transformation of MCTs to SCCs, but further investigations are necessary to evaluate the possible role of HPV in the malignant transformation of MCTs (12, 13). Since there is no determined agreement about the ideal management and prognostic factors of malignant transformation of MCTs, patient's characteristics, imaging findings,

laboratory evaluation, and pathology report, all should be considered together in determining the treatment plan chosen for the patient to achieve the best therapeutic results. At this time, chemotherapy is known as the first line of treatment for epithelial cell tumors of both squamous and non-squamous subgroups (7), however, the role of radiotherapy is still unclear (14).

Conclusion

Despite MCT with malignant transformation is a rare condition, clinicians, pathologists and radiologists should be aware of it especially in postmenopausal women because the treatment plan and the prognosis of the patient will be significantly different.

Ethical Permission

Written consent for publication of this case report was obtained from the patient.

Acknowledgments

The authors have no acknowledgement.

Conflict of Interest

The authors declared no conflict of interest.

References

1. Ayhan A, Bukulmez O, Genc C, Karamursel BS, Ayhan A. Mature cystic teratomas of the ovary: case series from one institution over 34 years. *Eur J Obstet Gynecol Reprod Biol.* 2000; 88(2):153-7. [DOI:10.1016/S0301-2115(99)00141-4]
2. Comerci Jr JT, Licciardi F, Bergh PA, Gregori C, Breen JL. Mature cystic teratoma: a clinicopathologic evaluation of 517 cases and review of the literature. *Obstet Gynecol.* 1994; 84(1):22-8.
3. Pradhan P, Thapa M. Dermoid cyst and its bizarre presentation. *J Nepal Med Assoc.* 2014; 52(52):837-44. [DOI:10.31729/jnma.2763]
4. Ye L-Y, Wang J-J, Liu D-R, Ding G-P, Cao L-P. Management of giant ovarian teratoma: a case series and review of the literature. *Oncol Lett.* 2012; 4(4):672-6. [DOI:10.3892/ol.2012.793] [PMID] [PMCID]
5. Kudva R, Ayachit GS, Ayachit A. Malignant melanoma arising in an ovarian mature cystic teratoma-a rare entity. *J Clin Diagn Res.* 2015; 9(4):ED14. [DOI:10.7860/JCDR/2015/12457.5817] [PMID] [PMCID]
6. Hurwitz J, Fenton A, McCluggage W, McKenna S. Squamous cell carcinoma arising in a dermoid cyst of the ovary: a case series. *BJOG: Int J Obstet Gynaecol.* 2007; 114(10):1283-7. [DOI:10.1111/j.1471-0528.2007.01478.x] [PMID]
7. Akazawa M, Onjo S. Malignant transformation of mature cystic teratoma: is squamous cell carcinoma different from the other types of neoplasm? *Int J Gynecol Cancer.* 2018; 28(9). [DOI:10.1097/IGC.0000000000001375] [PMID]

8. Wei F, Jiang Z, Yan C. Analysis of 20 mature ovarian cystic teratoma cases in postmenopausal women. *Chinese Med J*. 2001; 114(2):137-8.
9. Rim S-Y, Kim S-M, Choi H-S. Malignant transformation of ovarian mature cystic teratoma. *Int J Gynecol Cancer*. 2006;16(1). [[DOI:10.1111/j.1525-1438.2006.00285.x](https://doi.org/10.1111/j.1525-1438.2006.00285.x)] [[PMID](#)]
10. Li C, Zhang Q, Zhang S, Dong R, Sun C, Qiu C, et al. Squamous cell carcinoma transformation in mature cystic teratoma of the ovary: a systematic review. *BMC Cancer*. 2019; 19(1):1-12. [[DOI:10.1186/s12885-019-5393-y](https://doi.org/10.1186/s12885-019-5393-y)] [[PMID](#)] [[PMCID](#)]
11. Kurt S, Avşar HA, Doğan ÖE, Saatli HB, Saygılı U. Effects of mature cystic teratoma on reproductive health and malignant transformation: A retrospective analysis of 80 cases. *J Turk Ger Gynecol Assoc*. 2019; 20(2):84. [[DOI:10.4274/jtgga.galenos.2018.2018.0003](https://doi.org/10.4274/jtgga.galenos.2018.2018.0003)] [[PMID](#)] [[PMCID](#)]
12. Araujo IBdO, Pinheiro MV, Zanvettor PH, Studart EJ, Coupland SE. High frequency of malignant transformation of ovarian mature teratoma into squamous cell carcinoma in young patients in northeast Brazil. *Int J Gynecol Pathol*. 2016; 35(2):176-84. [[DOI:10.1097/PGP.0000000000000225](https://doi.org/10.1097/PGP.0000000000000225)] [[PMID](#)]
13. Liu L-C, Huang R-L, Lin Y-C, Lai H-C, Su H-Y, Chang F-W, et al. Squamous cell carcinoma arising from an ovarian teratoma related to human papillomavirus infection: using a PCR-based reverse-blot assay. *Taiwan J Obstet Gynecol*. 2011; 50(4):543. [[DOI:10.1016/j.tjog.2011.10.029](https://doi.org/10.1016/j.tjog.2011.10.029)] [[PMID](#)]
14. Goudeli C, Varytimiadi A, Koufopoulos N, Syrios J, Terzakis E. An ovarian mature cystic teratoma evolving in squamous cell carcinoma: A case report and review of the literature. *Gynecol Oncol Rep*. 2017;19:27-30. [[DOI:10.1016/j.gore.2016.12.005](https://doi.org/10.1016/j.gore.2016.12.005)] [[PMID](#)] [[PMCID](#)].

How to Cite This Article:

Shafizadeh F, Babazadeh S, Nasiri Amiri F, Shafizadeh A. Squamous Cell Carcinoma in the Shadow of the Mature Cystic Teratoma of the Ovary: A Case Report. *J Obstet Gynecol Cancer Res*. 2021; 6 (4) :233-238

Download citation:

[BibTeX](#) | [RIS](#) | [EndNote](#) | [Medlars](#) | [ProCite](#) | [Reference Manager](#) | [RefWorks](#)